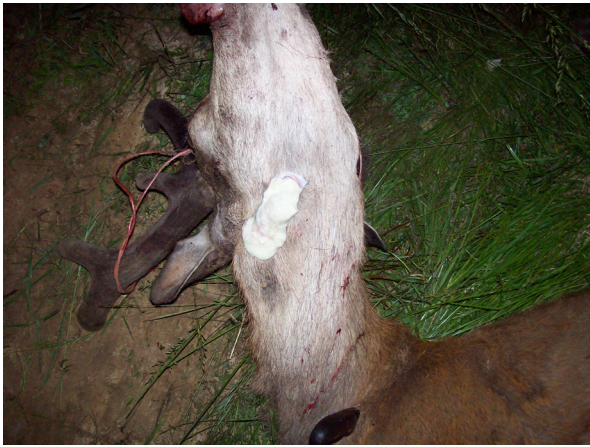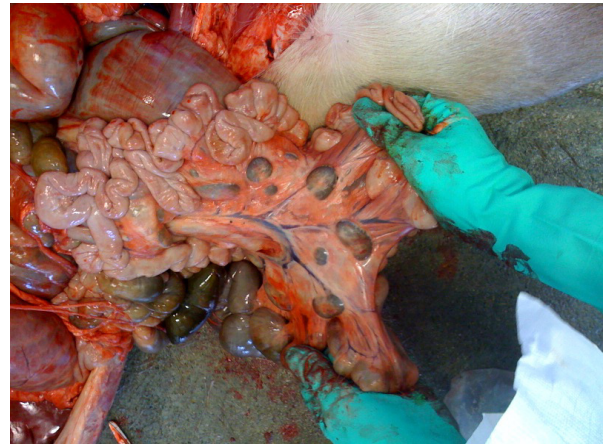


Bovine Tuberculosis Abscesses and Lesions



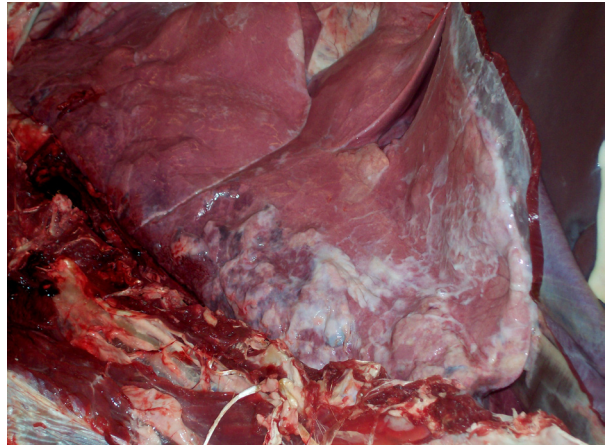
Abscessed lymph nodes in the neck. When ruptured, material is thick, yellowish or greenish without odor



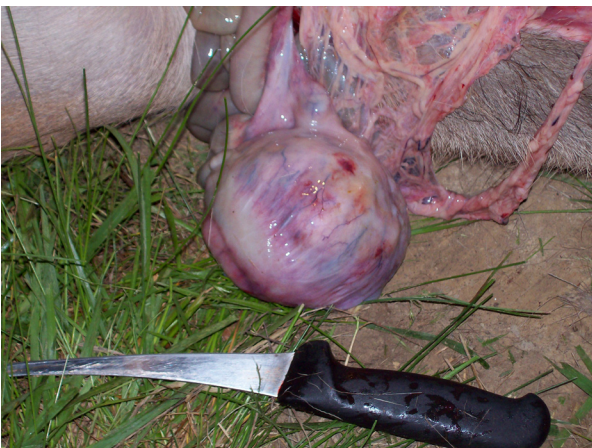
Abnormal lymph nodes; large and dark in color



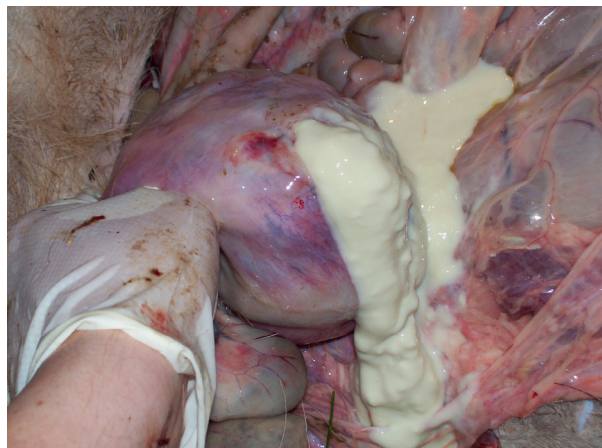
Pearl abscesses on inside lining of rib cage, may be as small as the tip of a finger



Lung lobes with chronic pneumonia and abscesses



Large abscess within abdominal cavity may be large (grapefruit-sized) or very small



If you see any lesions,
consult a veterinarian by calling (toll-free) at:
877/747-3038 ext. 358
More information available at: www.boah.in.gov

